

STEPS

STANDARDIZED TOOLBOX
OF EDUCATION FOR
PEDIATRIC SURGERY

Ingested Foreign Bodies

APSA Education Committee
2020-2021



APSA
American Pediatric
Surgical Association
Saving Lifetimes™

Brian A Jones, MD, FACS, FAAP

University of Chicago

Edited by:

Jill Whitehouse, MD and Eunice Huang, MD, MS

Patient 1 History

- 2-year-old boy is playing with his older sibling's piggy bank. 30 minutes later parents find he is drooling and has difficulty swallowing his lunch.

Discussion of History Elements

- What was ingested?
 - ~40% are unwitnessed
- Time of ingestion?
- When did symptoms start?
 - Vomiting, drooling, dysphagia, retrosternal pain, coughing, wheezing, choking
- What does patient have access to swallow?
 - Coins, batteries, magnets, fish bones, small toys
- Past Medical/Surgical Hx
 - Any prior esophageal operations
- ROS
 - Any other recent choking episodes

Physical Exam

- Awake, alert toddler
- No crepitus or neck tenderness
- Chest clear bilaterally
- Heart rate regular
- Abdomen soft, non-tender

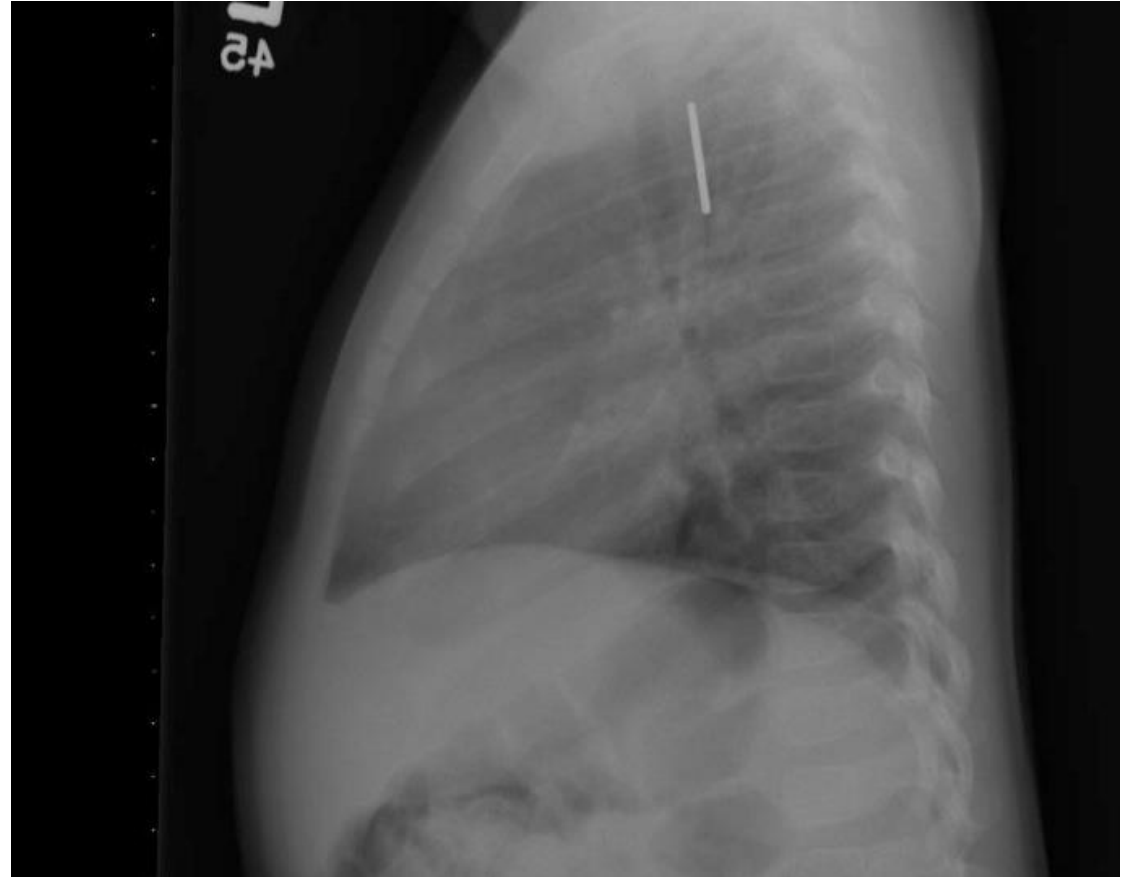
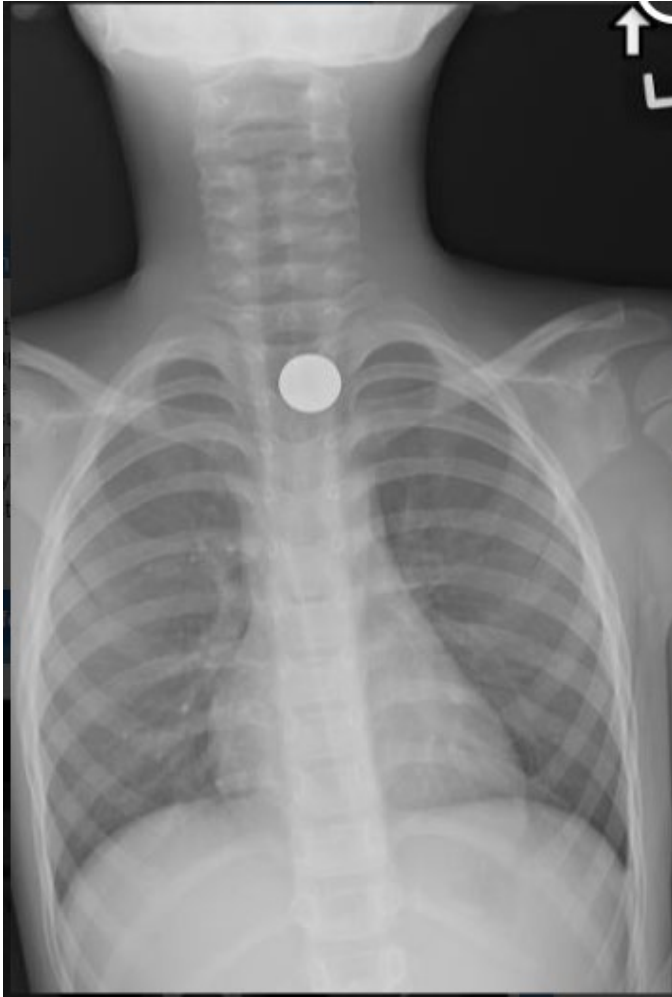
Pitfalls

- Symptoms may evolve as object moves down esophagus
 - Witnessed ingestions may be asymptomatic at presentation
- Preverbal children may have vague symptoms (fussiness, feeding intolerance)

Studies (Labs, Imaging)

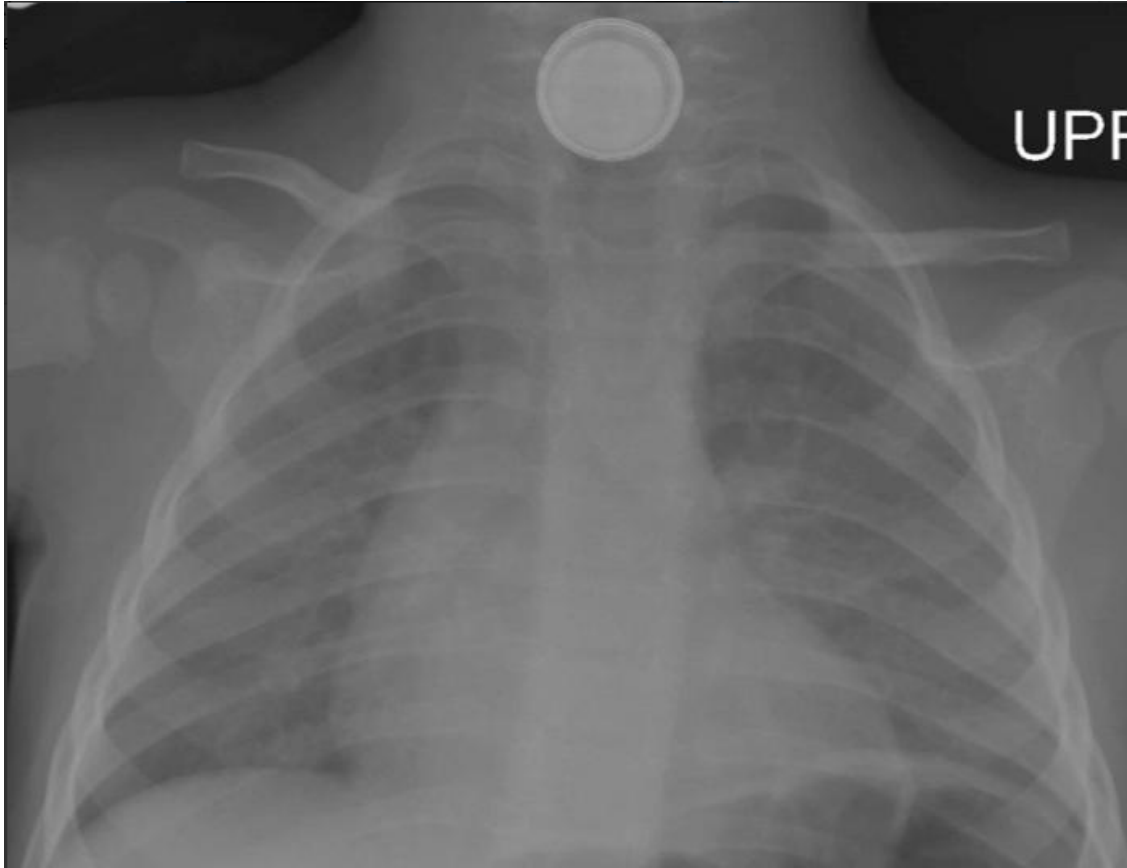
- What labs are needed?
 - Generally, none if patient is stable
- What imaging is needed?
 - PA/Lateral CXR
 - Diagnostic in 80% of esophageal FB ingestions
 - Less sensitive for small bones and non-radiopaque objects (toothpicks, plastic, food particles)
 - Fluoroscopy (Barium or water-soluble contrast)

Study Results

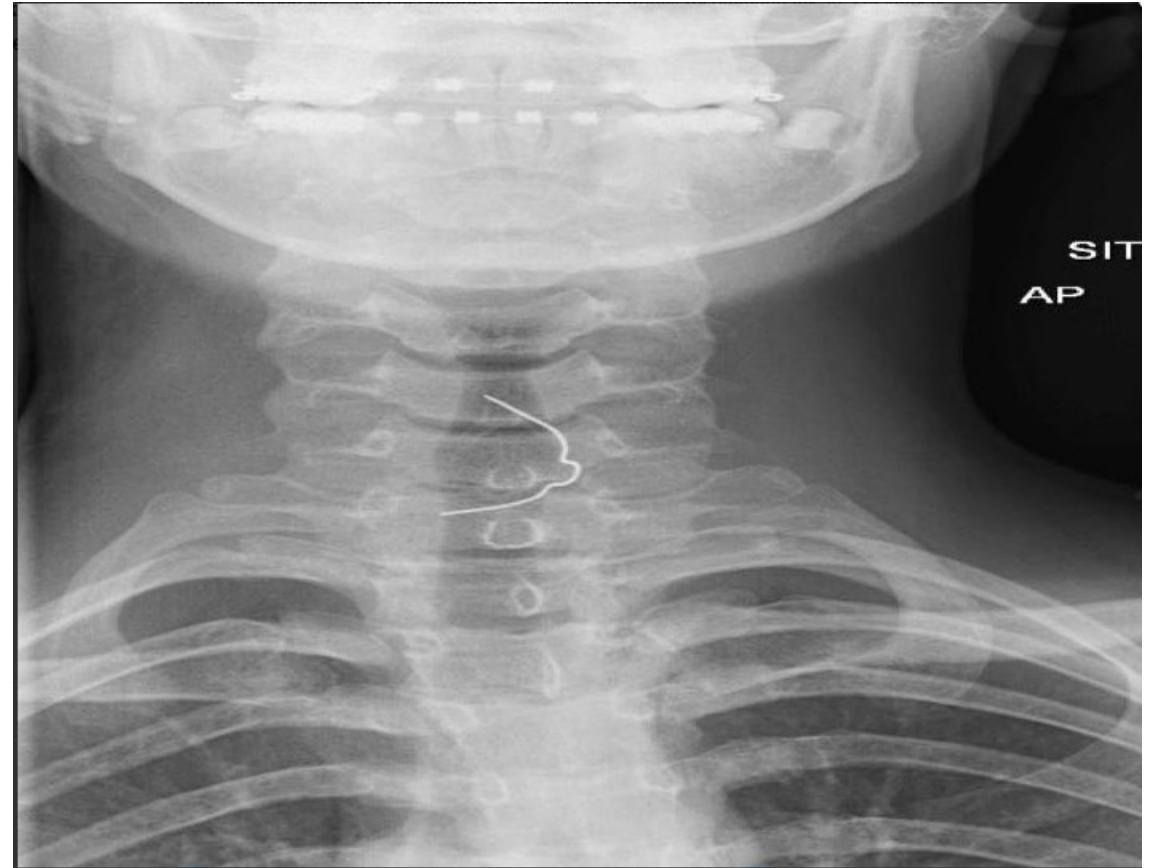


PA and lateral views of
coin in esophagus

Alternative CXR findings



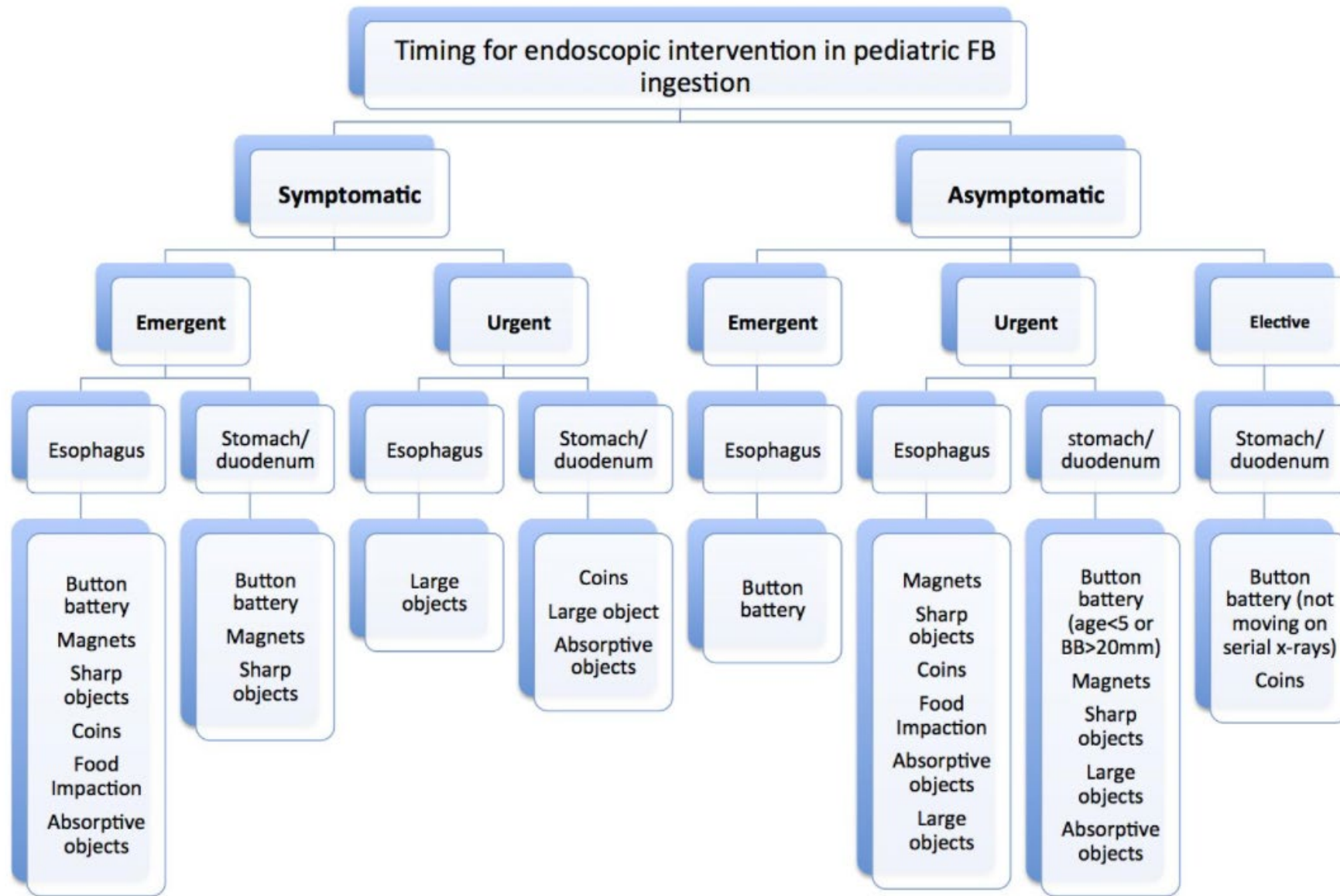
Button battery



Dental spacer

Case Discussion

- Diagnosis
 - Esophageal Foreign Body (coin)
- Management
 - Many objects will pass through GI tract
 - Exceptions to observation
 - Batteries, magnets, sharp objects
 - Complete esophageal obstruction
 - Object trapped at cricopharyngeus
 - Object entrapped >24 hrs



*Consider administering 10ml q10min oral honey en route to ER if button battery ingested.

Alternatives to Surgery

- Bougiennaige
 - Dilator size based on patient's age/weight
 - Patient placed on parent's lap and arms wrapped
 - Dilator passed to predetermined depth and removed
 - Repeat CXR
- Fluoroscopy with Foley catheter
 - 10 or 12Fr foley placed through nares under fluoroscopic guidance
 - Balloon inflated below level of coin
 - Catheter withdrawn until coin reaches oropharynx and is removed

Operation

- Rigid Endoscopy
 - Graspers with multiple jaw shapes
- Flexible Endoscopy
 - Adult gastroscope for children >10kg
- Most objects lie just below upper esophageal sphincter

Post-Op Management

- Peri-op
 - Most patients can be fed in PACU
 - Trauma during extraction or erosions/ulcerations may prompt a liquid diet post-op
- Long Term
 - If no esophageal pathology seen, no need for long term follow-up

Complications and Management

- >50% of esophageal perforations are iatrogenic
- 12% of esophageal perforations from Foreign body ingestions
 - May see ulcerations at endoscopy
 - Consider esophagram post-procedure if concern
 - Non-operative management may be acceptable in cases of contained leaks
 - Surgical intervention best if symptoms >24hrs

Patient 2 History

- 7-year-old boy tells his mother that while playing at a friend's house, he ate "some magnet toys." He is currently asymptomatic.

Discussion of History Elements

- What was ingested?
 - Number of magnets?
 - Other metal objects?
- Time of ingestion?
- When did symptoms start?
 - Vomiting, fever, abdominal pain
- What does patient have access to swallow?
 - Rare earth magnets, metal objects
- Past Medical/Surgical Hx
- ROS

Physical Exam

- Awake, alert boy
- Chest clear bilaterally
- Heart rate regular
- Abdomen soft, non-tender

Pitfalls

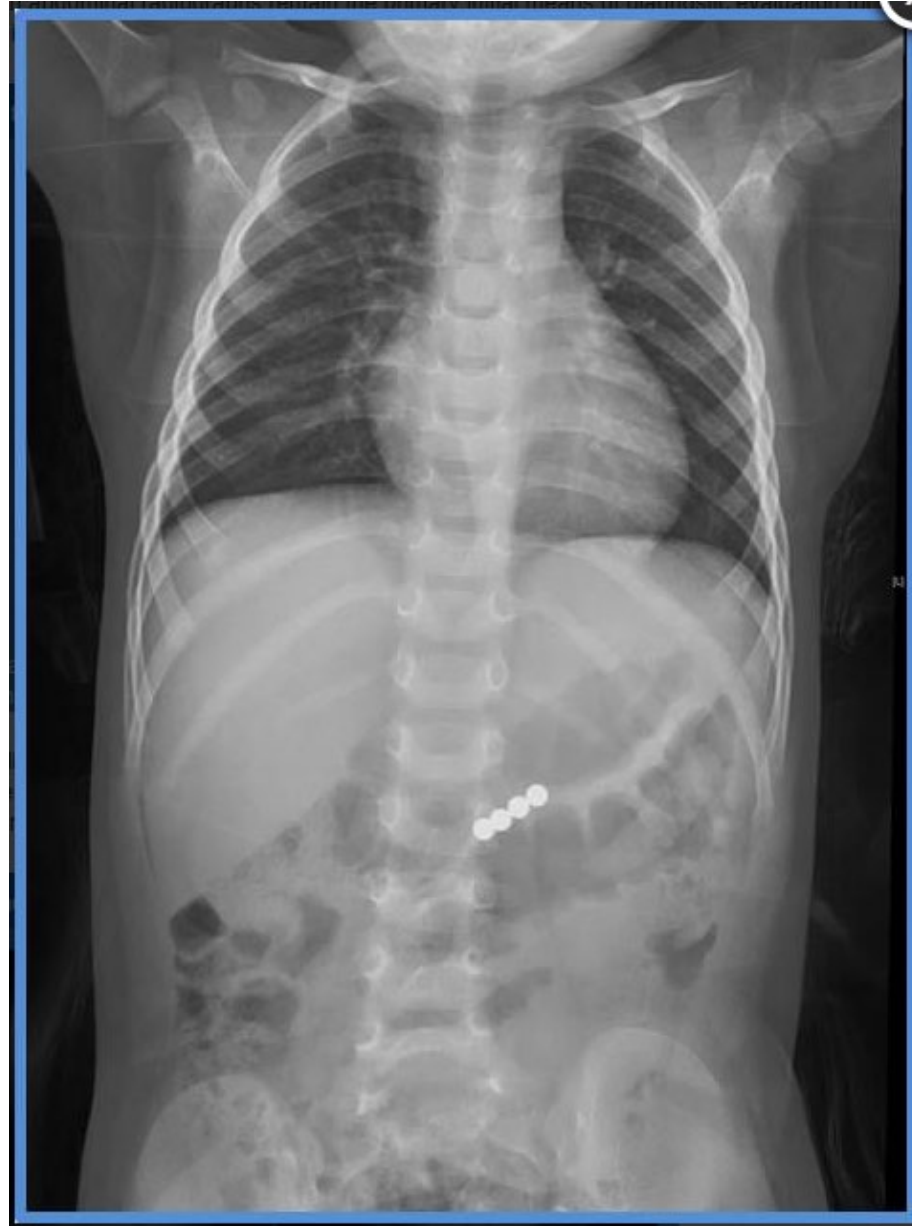- Single magnets will often pass through GI tract
- Ingesting multiple magnets, or a magnet and another metal object can cause the objects to magnetically “connect” across bowel loops leading to erosion, fistula formation, perforation, and bowel obstructions
- Symptoms can arise hours to days after ingestion

Studies (Labs, Imaging)

- What labs are needed?
 - Generally, none if patient is stable
- What imaging is needed?
 - Plain films
 - Magnets and metallic objects should be readily visible on KUB
 - Multiple views can help elucidate number of magnets

Study Results

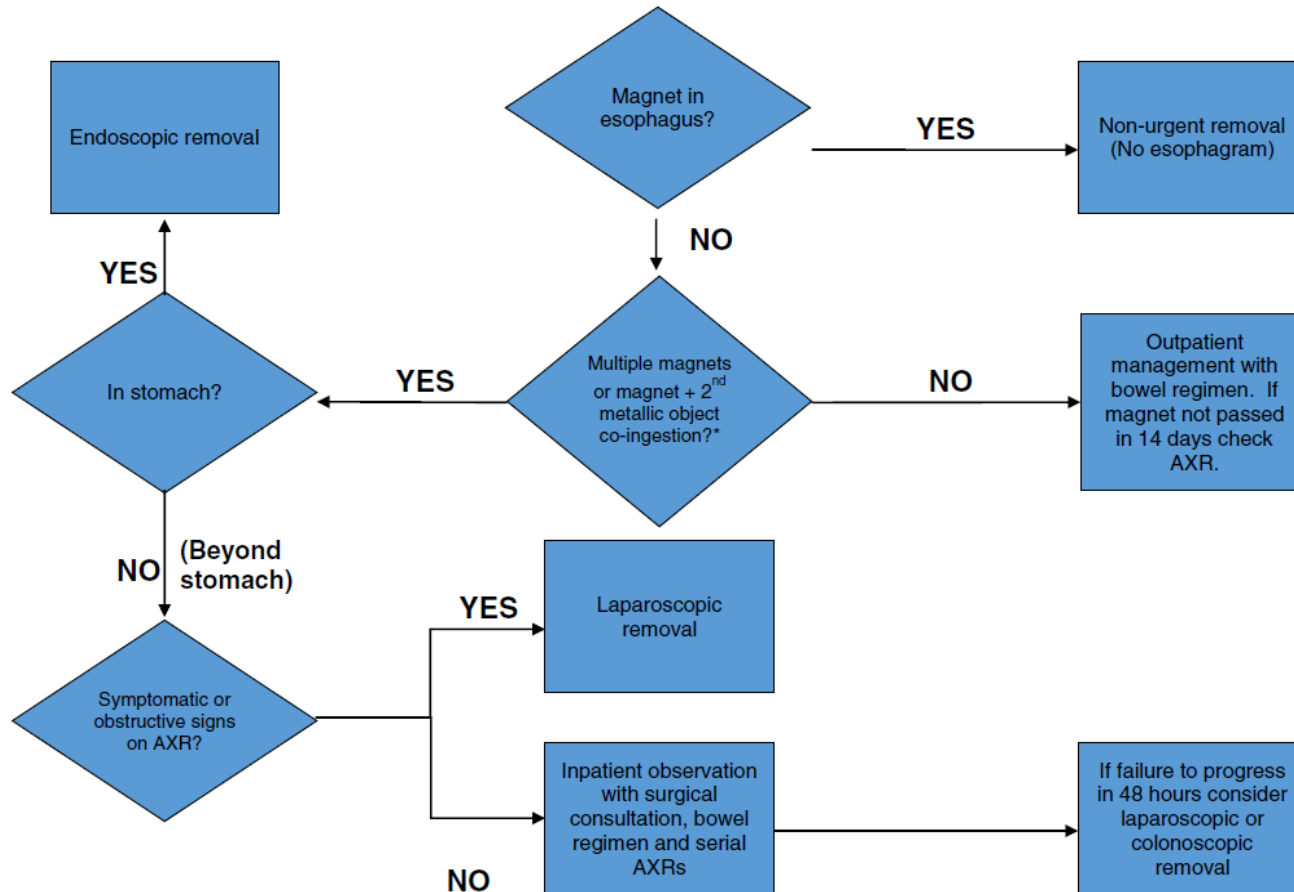
Multiple rare earth magnet toys



Alternatives to Surgery

- Asymptomatic patients with magnets distal to the pylorus may be candidates for observation
- Serial imaging
- Administration of bowel prep to facilitate antegrade movement of the foreign bodies
- Development of symptoms or failure of the magnets to move on serial imaging are indications for operative exploration

Possible Management Algorithm



*If a single magnet vs. multiple magnet ingestion cannot be definitively differentiated by history and radiographic findings, then the patient should be treated as an inpatient for suspicion of ingestion of multiple magnets.

R. Sola Jr et al. / Journal of Pediatric Surgery 53 (2018) 1815–1819

Operation

- Laparoscopy
 - Magnets may attract to ends of graspers
- Laparotomy
 - Bowel obstruction may limit visibility
- Intra-operative fluoroscopy
 - Helpful to find magnets and confirm all have been removed

Patient 3 History

- 2-year-old boy began choking while eating peanuts. He presents to the ER approximately 30 minutes later with mild wheezing.

Discussion of History Elements

- What was ingested?
- Time of ingestion?
- When did symptoms start?
 - coughing, wheezing, respiratory distress
- What does patient have access to swallow?
- Past Medical/Surgical Hx
- ROS
- Allergies?

Physical Exam

- Awake, alert boy
- Breath sounds clear on right, diminished on left
- Heart rate regular
- Abdomen soft, non-tender

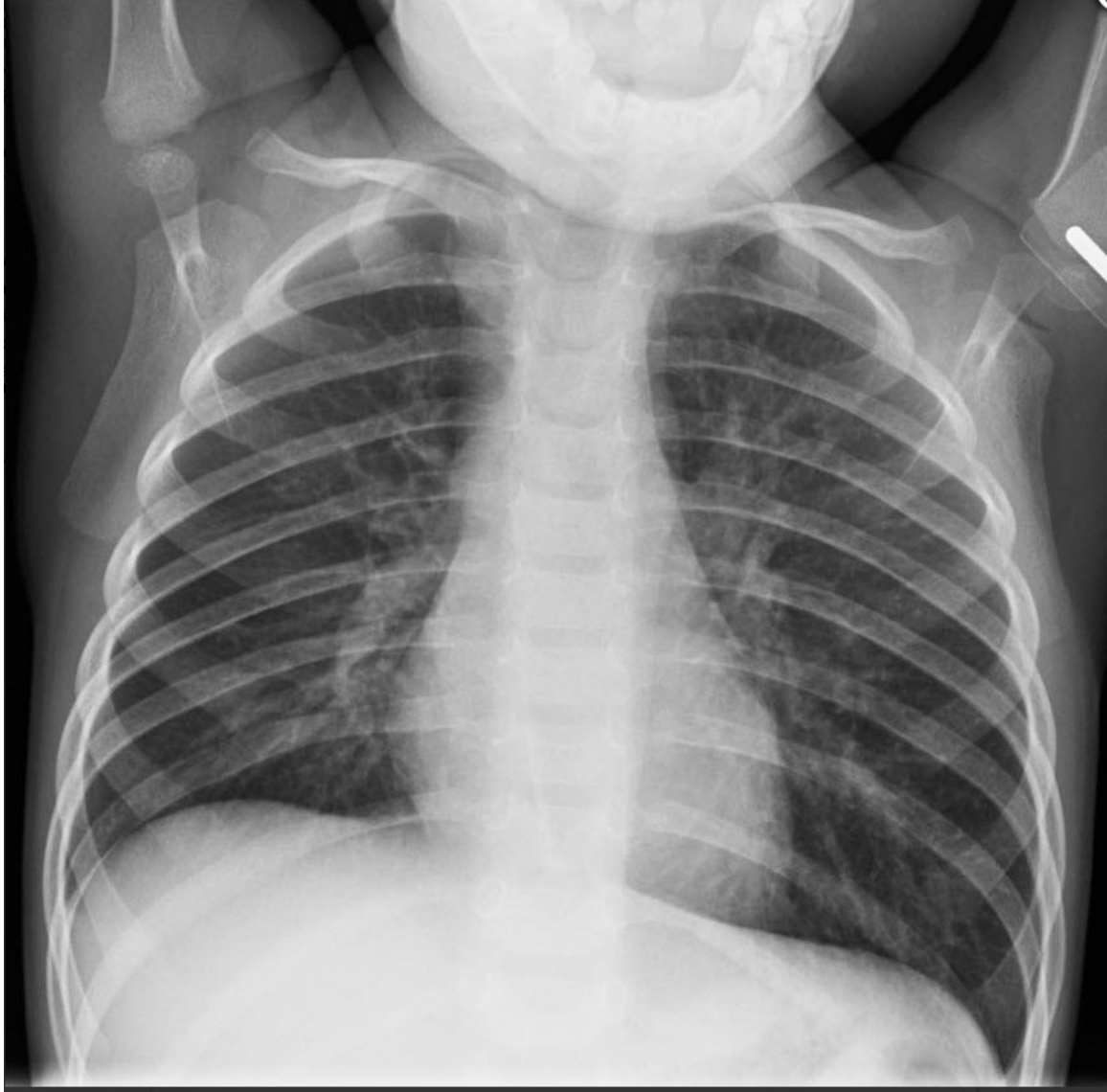Pitfalls

- Airway foreign bodies can create a “ball valve” effect which causes air trapping and hyperinflation
- Asthma, anaphylaxis, angioedema and vocal cord dysfunction can mimic the symptoms of airway foreign bodies
- Delayed presentations may have symptoms of cough and dyspnea

Studies (Labs, Imaging)

- What labs are needed?
 - Generally, none if patient is stable
- What imaging is needed?
 - Plain films
 - Inhalation and exhalation films may identify air trapping
 - Many airway foreign bodies are not radiopaque

Study Results



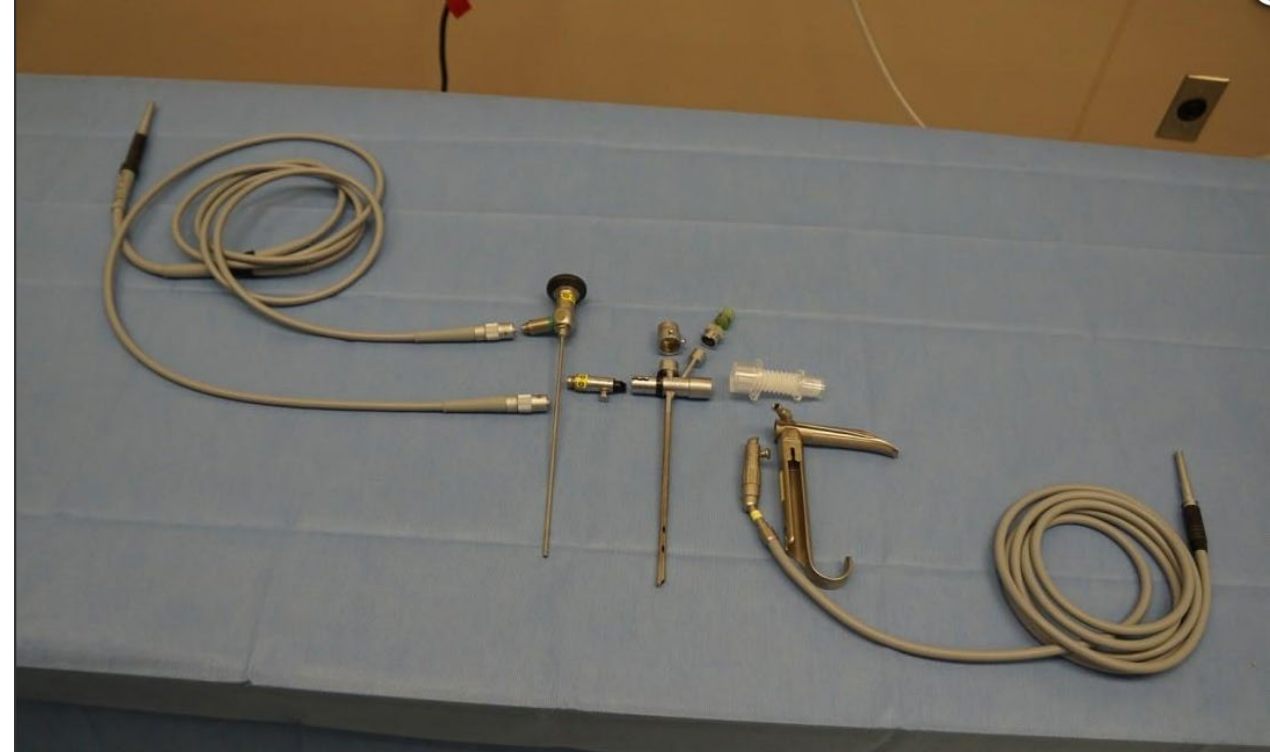
Air trapping and hyperinflation of left lung

Alternatives to Surgery

- Any concern for airway obstruction, worsening respiratory status, or tracheal/bronchial disease should warrant immediate laryngo-bronchoscopic evaluation
- Tripod posture, choking, difficulty swallowing, drooling, fatigue and tachypnea are signs of impending respiratory collapse

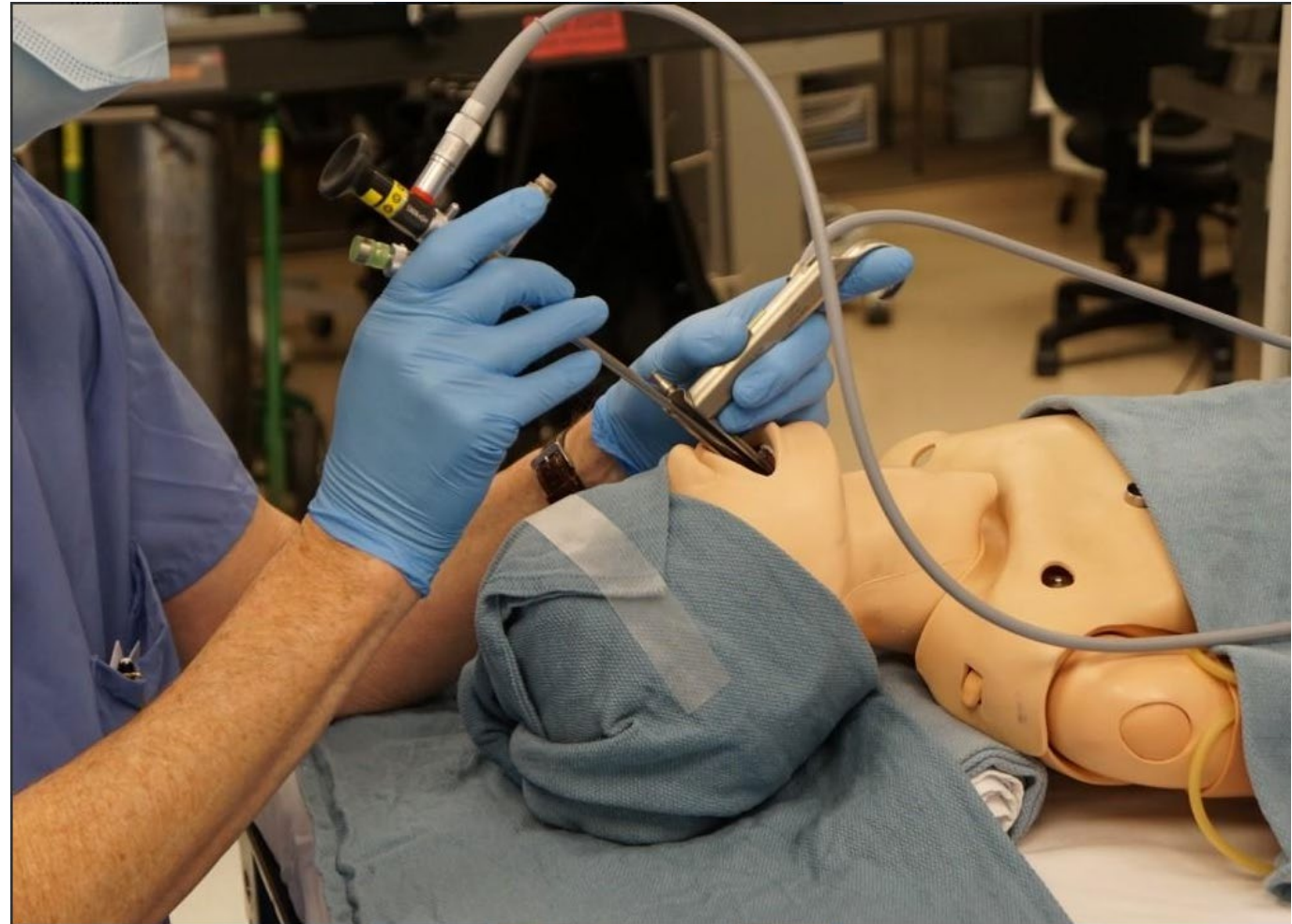
Operation

- Rigid bronchoscopy
 - Optimal visualization of oropharynx, larynx and airways
 - Improved control over airway when compared to flexible bronchoscopy
 - Ensure equipment and suction is properly assembled and available



Operation

- Position patient with neck extended
- Use laryngoscope to visualize airway
- Place rigid bronchoscope thru vocal cords



Post-Op Management

- CXR
 - Should be obtained in recovery room
 - Evaluate for atelectasis, PTX
- Long Term
 - If no airway pathology seen, no need for long term follow-up

Complications and Management

- Distal foreign bodies can be retrieved with Fogarty balloon
 - Pass catheter distal to foreign body, inflate balloon, and slowly withdraw
- Chronic foreign bodies may have mucus plugging behind them that dislodges with removal
- Emergency airway kit should be available in OR

Question 1

- Which of the following ingested foreign bodies represents a surgical emergency?
 - A. Coin in upper esophagus
 - B. Coin in stomach
 - C. Button battery in upper esophagus
 - D. Button battery in stomach
 - E. Toothbrush in stomach

Question 1

- Which of the following ingested foreign bodies represents a surgical emergency?
 - A. Coin in upper esophagus
 - B. Coin in stomach
 - **C. Button battery in upper esophagus**
 - D. Button battery in stomach
 - E. Toothbrush in stomach

Question 2

- Where is an ingested foreign body most likely to become lodged in the GI tract?
- A. Cricopharyngeus
- B. Gastroesophageal junction
- C. Pylorus
- D. C-loop of the duodenum
- E. Ileocecal valve

Question 2

- Where is an ingested foreign body most likely to become lodged in the GI tract?
- **A. Cricopharyngeus**
- B. Gastroesophageal junction
- C. Pylorus
- D. C-loop of the duodenum
- E. Ileocecal valve

Question 3

- Which of the following KUB findings should prompt immediate surgical exploration?
 - A. Single magnet in small intestine
 - B. Linear linked magnets in normal small bowel
 - C. Linked magnets with evidence of small bowel obstruction
 - D. Linear linked magnets in normal colon
 - E. Linear linked magnets in normal stomach

Question 3

- Which of the following KUB findings should prompt immediate surgical exploration?
 - A. Single magnet in small intestine
 - B. Linear linked magnets in normal small bowel
 - **C. Linked magnets with evidence of small bowel obstruction**
 - D. Linear linked magnets in normal colon
 - E. Linear linked magnets in normal stomach

Final Discussion/Review

- Ingested foreign objects can cause significant morbidity and mortality
- Button batteries in the esophagus are a surgical emergency
- Ingestion of multiple magnets can lead to erosion, fistulization, and bowel perforation
- Airway foreign bodies are frequently not radiopaque

References

- Ruiz-Elizalde AR, Gander J, et al. Gastrointestinal foreign bodies, in Pediatric Surgery NaT
- Gander J, Grabski D. Esophageal foreign bodies, in Pediatric Surgery NaT
- Schneider J. Intestinal Foreign Bodies, in Pediatric Surgery NaT
- Sola Jr R, Rosenfeld, EH, et al. Magnet foreign body ingestion: rare occurrence but big consequences. J Pediatr Surg 2018;53:1815-19.
- Glenn IC, DeAntonio JH, et al. Airway foreign bodies, in Pediatric Surgery NaT
- Glenn IC, DeAntonio JH, et al. Bronchoscopy, in Pediatric Surgery NaT
- National Capital Poison Center Button Battery Ingestion Triage and Treatment Guideline, 2022. <https://www.poison.org/battery/guideline>

Acknowledgement Slide

The preceding educational materials were made available through the
American Pediatric Surgical Association

In order to improve our educational materials we welcome your comments/ suggestions:
www.eapsa.org